

In-stent Restenosis and Correlation of Erectile Dysfunction Drug Application in Diabetic Patient

Muzakkir Amir ¹, Rini Anastasia²¹ Department of Cardiology and Vascular Medicine, Hasanuddin University, Makassar, Indonesia;² Cardiac Center of WahidinSudirohusodo Hospital Makassar, Indonesia

ABSTRACT

During the past several years, coronary stent has been improving , but the in-stent restenosis still remains a challenging problems specially in diabetic patient. Several recent studies have provide the available options for treating or reducing the incidence of ISR And lately they have been propose promising outcome in delayed or preventing ISR through Dysfunction erection (DE) drugs and its application in coronary stent or after stent implantation. We present a case of ISR in diabetic patient with application of DE drugs.

Keywords : Instent restenosis, coronary stent, diabetic patient, dysfunction erection drugs

BACKGROUND

In stent restenosis (ISR) is a condition where there is a reduction or re-narrowing diameter of blood vessel after coronary stent implantation was performed. The incidence of Instent restenosis (ISR) cannot be validated with certainty because it numerous risk factors that can initiated the progressivity, these factors include age and diabetes mellitus.

The development of use in coronary stents that have changed from BMS, DES and also the use of balloon coating drugs does not show a significant change in the incidence of ISR, although DES is considered to reducing the incidence of ISR but cannot properly inhibit proliferation of blood vessel that causes ISR. This is what underlies the existence of various studies to canvas the effects of drugs that can be used to reduce the incidence of ISR.

Recently, there have been studies that shown evidence of a reduction in vascular proliferation by using drugs that have been routinely used to treat erectile dysfunction, the phosphodiesterase 5 (PDE5) inhibitor which functions as a vasodilator that currently under investigation the effect in overcoming ISR in coronary stents or consumed regularly as oral medicine

CASE PRESENTATION

A 63 years old male patient with a history of uncontrolled Diabetes Mellitus and Erectile Dysfunction (ED) was hospitalized in September 2018 with Acute Coronary Syndrome. The patient had an intracavernosal injection with the combination of alprostadil, papaverine, and phentolamine, he also had routinely using sildenafil to relieve ED symptoms. In February 2018 patient had undergone PCI with implantation of two DES in RCA. Physical examination within normal limit.

RELEVANT TEST RESULTS PRIOR TO CATHETERIZATION

Electrocardiogram (ECG) shows inverted T in lead I, aVL, V5-V6 and Q-pathology in III, aVF. [Fig 1] Laboratory finding remarkable for elevated cardiac biomarker (Troponin I: 8,57ng/ml) and Echocardiography result of hypokinesia in the inferior and anterior wall with LVEF 32%, diastolic dysfunction grade 2.

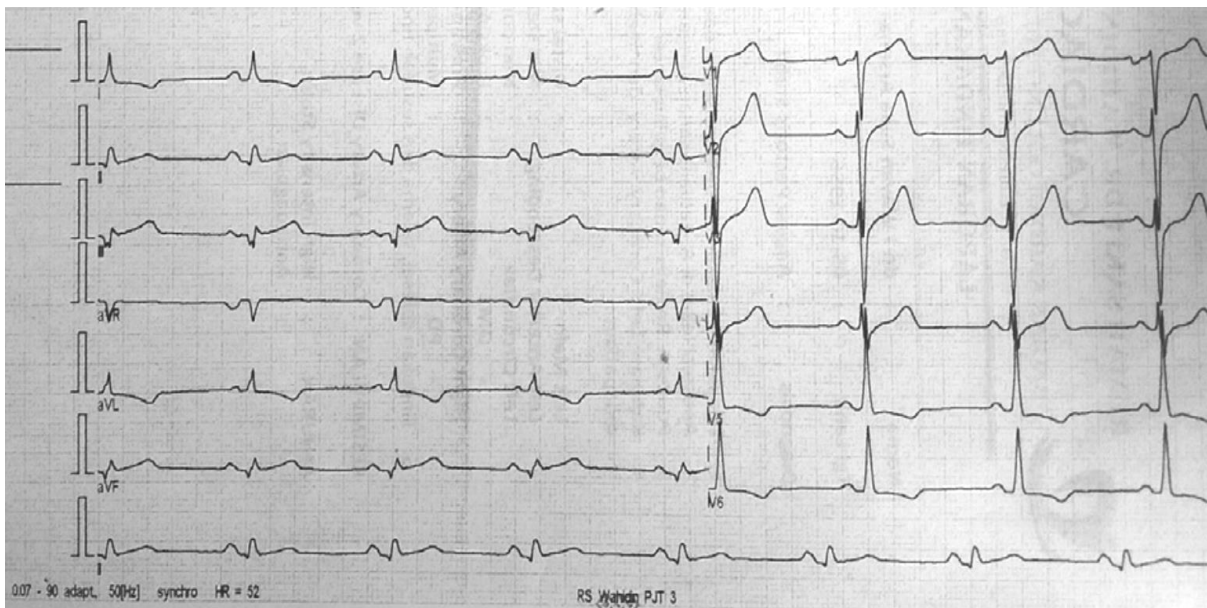


Figure 1

RELEVANT CATHETERIZATION FINDINGS

Angiography result after PCI (implantation of two stent DES in RCA) in February 2018 showed TIMI 3 Flow with no dissection nor residual stenosis. [Fig 2]

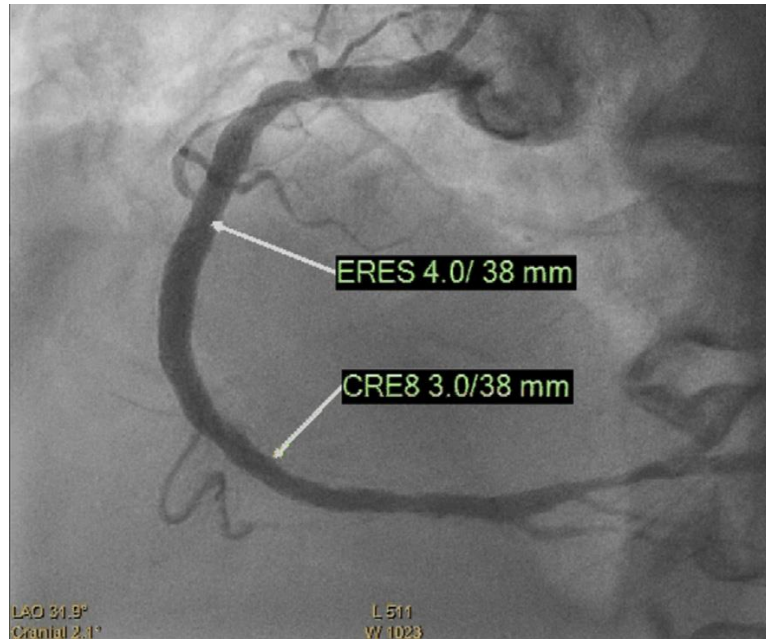


Figure 2

INTERVENTIONAL MANAGEMENT

Procedural Step.

During the procedure, the right coronary artery was cannulated with a 6F Judskin right guiding catheter through radial access, then wiring with Terumo Run-through Floppy through proximal RCA. Predilatation with balloon Maverick 2.0 x 20 mm with pressure 12 atm, then wiring continue through distal RCA. We implanted 2 DES. First DES (ERES 4.0 x 38 mm) planted in proximal RCA with pressure 10 atm, another DES (Cre-8 3.0x 38mm) planted with pressure 14 atm at distal RCA overlapped at the first one. Angiography result after PCI showed TIMI 3 flow, no evidence of dissection, perforation nor residual stenosis.

He apparently asymptomatic and continued using DE drugs aside with coronary artery disease medicine till a few days before admission to the hospital with ongoing chest pain and arrhythmia. An EP-Study and angiogram performed in 3 October 2018 due to present of arrhythmia and recurrent angina. The angiogram revealed in-stent restenosis in the proximal and distal stenosis of RCA.[Fig 3]

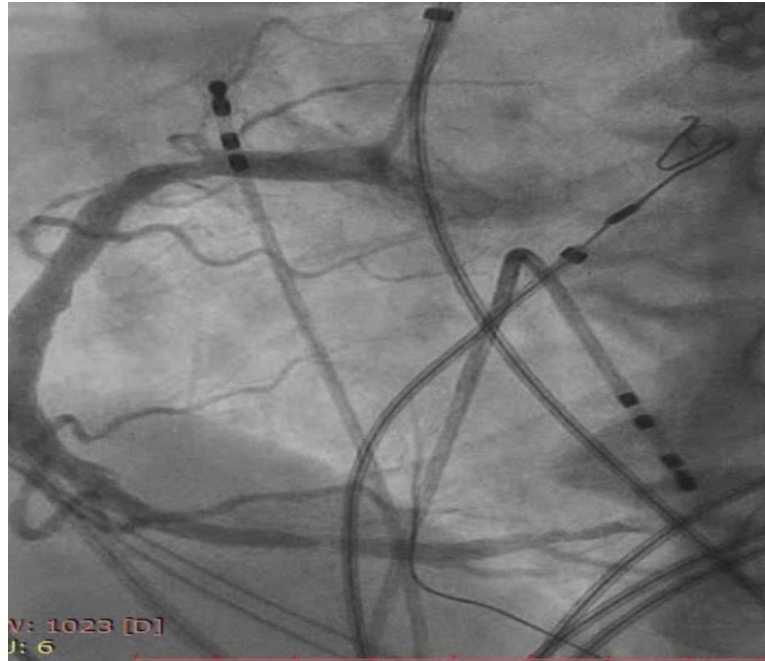

Figure 3

DISCUSSION

The application of DES has proven reduced restenosis rates compared with BMS. In several studies, restenosis rates after implantation of DES decrease about 10%. The predictor of restenosis in BMS era such as diabetes melitus still significant in the era of DES. Eventough the rate of restenosis has decreased but neointimal proliferation still remain important clinical issue.

The upswing management of in stent restenosis can be seen through the alteration of coronary stents and post implantation stent therapy. Recently, experiment study that conducted in animal using DE drugs reveals an enlightening way to detain the neointimal formation. The result likely have promising way to bring prevention of restenosis.

In this case, patient has numerous factors that can trigger in stent restenosis, and it has progressing the restenosis in duration of 6 month. Although the patient has no acute symptom after the implantation stent, but he revealed the symptoms parallel to restenosis. The combining of CAD therapy and routinely use of ED drugs seems has no effect in delaying the progresitivity of in stent restenosis in this diabetic patient.

SUMMARY

Application of DE drugs in some studies propose promising improvement of declining incidence of ISR. But in this case, the experience in engage of DE drugs with CAD medicine

seems have no real effect in preventing ISR. But there was some other risk factor that may involving due to progression of ISR and made the application of DE drugs seems have ambiguous effect.

REFERENCE

Pleva L, Kukla P, Hlinomaz O. Treatment of coronary in-stent restenosis: a systematic review. *Journal of geriatric cardiology: JGC*. 2018 Feb;15(2):173.

Looser PM, Kim LK, Feldman DN. In-stent restenosis: pathophysiology and treatment. *Current treatment options in cardiovascular medicine*. 2016 Feb 1;18(2):10.

Alraies MC, Darmoch F, Tummala R, Waksman R. Diagnosis and management challenges of in-stent restenosis in coronary arteries. *World journal of cardiology*. 2017 Aug 26;9(8):640.

Her AY, Shin ES. Current management of in-stent restenosis. *Korean circulation journal*. 2018 May;48(5):337-49.

Yang HM, Jin S, Jang H, Kim JY, Lee JE, Kim J, Kim HS. Sildenafil Reduces Neointimal Hyperplasia after Angioplasty and Inhibits Platelet Aggregation via Activation of cGMP-dependent Protein Kinase. *Scientific reports*. 2019 May 23;9(1):7769.